

Necrotizing Fasciitis as Complication of Combined Use of Bevacizumab with Chemotherapy

© Cantürk Emir, © Can Aktaş, © Alp Giray Aydın

Koç University Hospital, Clinic of Emergency Medicine, İstanbul, Turkey

Abstract

Necrotizing fasciitis (NF) is an uncommon, severe, life-threatening soft tissue infection involving the subcutaneous tissue. Immunocompromised and patients with diabetes are at a higher risk of developing NF. One of the pathophysiologic mechanisms of NF is subcutaneous arterie thrombosis and tissue ischemia. Bevacizumab, a agent used in cancer treatment, blocks the activity of the vascular endothelial growth factor receptor. Recently, it is used along with paclitaxel and carboplatin due to an increased survival rate. The frequent use of this combination caused patients to applied to the emergency department (ED) with some side effects. NF is one of the rare side effects of this combination. Here, we present a patient with ovarian cancer who was admitted to the ED with severe leg pain, whose initial examination and tests were normal, and then NF developed within hours and then arrested.

Keywords: Fasciitis, necrotizing, drug therapy, bevacizumab, emergencies

Introduction

Cancer is one of the most common and fatal diseases in the modern era. Current treatment options are traditional chemotherapeutic agents, antiangiogenic therapy, and immunotherapy. Antiangiogenic agents are important for treating many solid tumors. Vascular endothelial growth factor is an important target for therapy as it is the primary mediator in angiogenesis and induced by multiple stimuli in tumor development (1). Bevacizumab, one of the antiangiogenic agents (2,3), shows a significant success rate for treating non-small-cell lung cancer and colorectal, gastric, and ovarian cancer (4). Recently, it is used along with paclitaxel and carboplatin due to the increased non-progressive survival rate in the long term. It is more widely used because of these promising research, but emergency admissions are also increasing due to the various side effects. Necrotizing fasciitis (NF) is reported in a few cases as one of the side effects of bevacizumab treatment. Traditional chemotherapeutic agents can also cause several side effects, and there are cases of NF reported after the combination treatment of bevacizumab and paclitaxel (5,6).

Here, we report a patient with NF because of a combination treatment of bevacizumab, carboplatin, and paclitaxel in a patient with ovarian cancer, admitted to the emergency department (ED).

Case Report

A 65-year-old female patient came to ED with pain on the outer side of her left leg and cramps on the left foot dorsum. She described the severity of her pain as 10/10. Her medical history includes hypertension and ovarian cancer diagnosed 2 months ago with liver metastases, and rectum invasion. Her surgical history includes cholecystectomy, splenectomy, total abdominal salpingoophorectomy, omentectomy, and appendectomy. After surgery, she was started on bevacizumab, paclitaxel, and carboplatin combination therapy. She took her second dose of treatment 10 days ago. Lower extremity physical examination findings were completely normal. Homans test was negative, the extremities were warm, and pulses were equal bilaterally. Lower extremity color Doppler ultrasound (USG) was ordered. Blood flow was evaluated as normal. No deep vein thrombosis and no superficial venous thrombophlebitis were found. In the



Corresponding Author: Can Aktaş MD, Koç University Hospital, Clinic of Emergency Medicine, İstanbul, Turkey
Phone: +90 532 566 51 92 **E-mail:** canaktas@gmail.com **ORCID ID:** orcid.org/0000-0002-2980-6652

Cite this article as: Emir C, Aktaş C, Aydın AG. Necrotizing Fasciitis as Complication of Combined Use of Bevacizumab with Chemotherapy. Eurasian J Emerg Med. 2023;22(1): 55-7.

©Copyright 2023 by the Emergency Medicine Physicians' Association of Turkey
Eurasian Journal of Emergency Medicine published by Galenos Publishing House.

Received: 01.04.2021
Accepted: 07.06.2021

superficial USG exam to the left lateral cruris, no pathologies were detected in cutaneous and subcutaneous tissues. Blood tests were unremarkable. As analgesic treatment, the patient was given paracetamol 10 mg/mL intravenous (IV), dexketoprofen 50 mg IV, and tramadol hcl 100 mg IV in ED. After treatment, her pain diminished and since no pathologies were detected and she was discharged.

After 4 h of her discharge, she came to ED with pain, ecchymosis, and edema in her left leg. She was agitated. Blood pressure: 90/60 mmHg, respiratory rate: 16/min, pulse: 98/min, SpO₂: 99%. In the lower extremity examination, her lower 1/3 thigh and lower leg were ecchymotic, edematous, and there was subcutaneous crepitation to palpation. Femoral pulses were present, and distal pulses were weak and palpable. 2-view radiographs of the cruris were ordered; there were subcutaneous air densities lateral to knee joint soft tissue and on the fibula (Figure 1). Lower extremity Doppler USG was performed. subcutaneous fat tissue increased, there was 6 mm effusion between the fat tissue and fascia, with comet artifacts. Left lower extremity computed tomography was performed. Air densities on the femoral vein, saphena magna; on vascular traces through the popliteal fossa, cruris and foot; on distal leg, knee and cruris level were commented as NF (Figures 2, 3). Infectious diseases and orthopedics were consulted. Meropenem 1 gr IV, metronidazole 500 mg IV was given in ED. While planning the patient's hospitalization, the patient was suddenly arrested in the ED and CPR was performed, but the patient was unresponsive.

Discussion

NF most frequently involves the abdominal wall, peritoneal membranes, and lower extremities. NF cases have been reported as more likely to arise in the presence of human immunodeficiency virus infection, diabetes, cancer, alcoholism, vascular insufficiencies, organ transplant - related immunodeficiencies, and chronic diseases (7). The use of bevacizumab and paclitaxel were reported as a cause of NF. In 2013, during a safety research conducted for bevacizumab therapy, 52 NF cases and 17 related deaths were reported from November 1997 to September 2012 (8). NF has been recorded as one of the side effects since 2013. The world Health Organization reported 7 NF cases developed after paclitaxel use as a combination therapy with bevacizumab (9). The case we presented supports the literature that bevacizumab and paclitaxel combination therapy increases the risk of developing NF. Although the mechanism is unclear, the progression rate of NF can last days from its beginning or develop quickly in hours ending up with death. In our case, the disease showed a rapid course and resulted in death within a few hours.

Conclusion

Although it is a rare complication, physicians should be reminded of the fact that patients admitted to ED with acute extremity pain and who are taking combined bevacizumab and paclitaxel therapy, carry a risk of having NF with rapid progression and death.

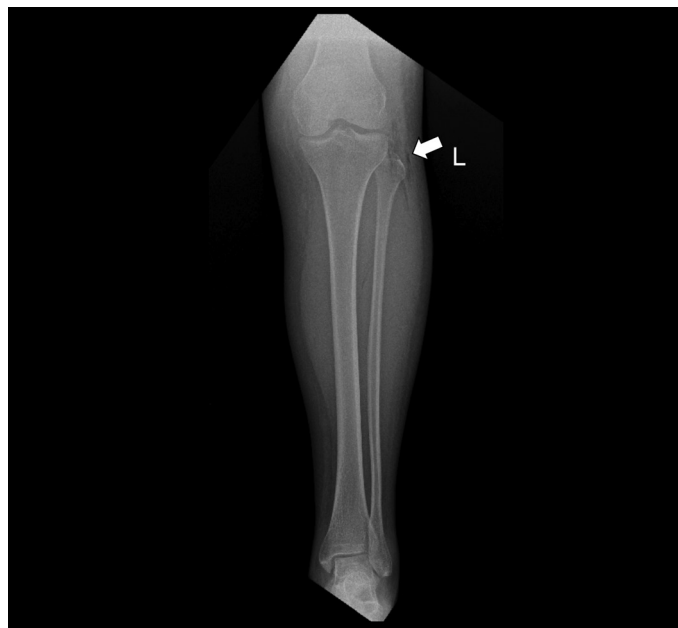

Figure 1. Left knee X-ray. Subcutaneous air densities in the superposed area over the soft tissues and fibula, adjacent to the lateral side of the knee joint

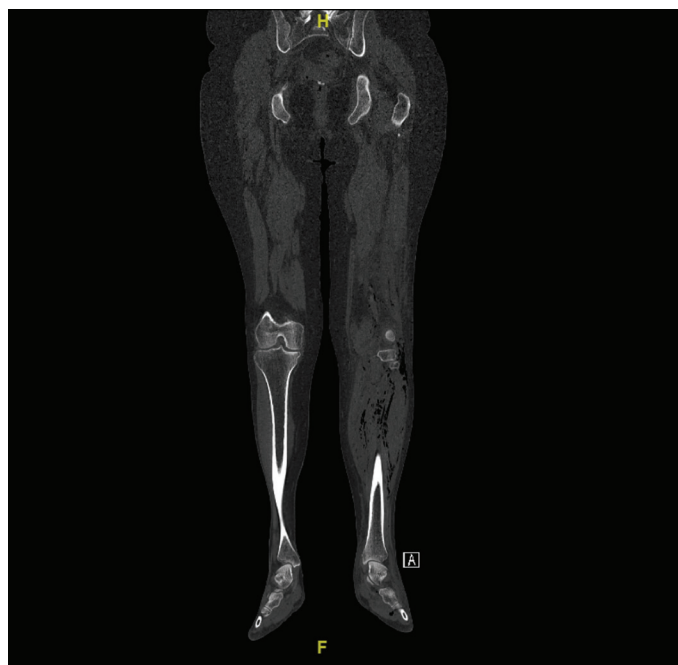

Figure 2. Lower extremity computed tomography. Air densities at the knee and cruris levels

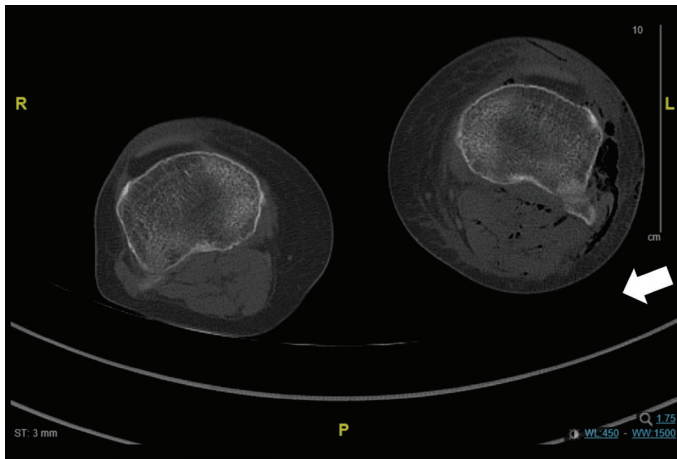


Figure 3. Lower extremity computed tomography

Ethics

Informed Consent: Consent form was filled out by all participants.

Peer-review: Externally peer-reviewed.

Authorship Contributions

Design: C.A., Data Collection or Processing: C.E., Literature Search: A.G.A., Writing: C.E.

Conflict of Interest: No conflict of interest was declared by the authors.

Financial Disclosure: The authors declared that this study received no financial support.

References

1. Vokes E, Herbst R, Sandler A. Angiogenesis inhibition in the treatment of lung cancer. *Clin Adv Hematol Oncol.* 2006;4:1-10.
2. Fujiwara K, Monk BJ, Lhommé C, Coleman RL, Brize A, Oaknin A, et al. Health-related quality of life in women with recurrent ovarian cancer receiving paclitaxel plus trebananib or placebo (TRINOVA-1). *Ann Oncol.* 2016;27:1006-13.
3. Klag N, Walter AC, Sheely KM, Manahan KJ, Geisler JP. Is the routine use of bevacizumab in the treatment of women with advanced or recurrent cancer of the cervix sustainable? *Clinicoecon Outcomes Res.* 2016;8:287-91.
4. Cong J, Liu R, Hou J, Wang X, Jiang H, Wang J. Therapeutic effect of bevacizumab combined with paclitaxel and carboplatin on recurrent ovarian cancer. *J BUON.* 2019;24:1003-8.
5. Bilton BD, Zibari GB, McMillan RW, Aultman DF, Dunn G, McDonald JC. Aggressive surgical management of necrotizing fasciitis serves to decrease mortality: a retrospective study. *Am Surg.* 1998;64:397-400.
6. Akbaş T, Bilgin H, Aykut U, Karakurt S. Nekrotizan Fasiit: Gecikmiş Cerrahi Müdahale Mortaliteyi Artırır. *DÜ Sağlık Bil Enst Derg.* 2015;5:84-8.
7. Modlinska A, Osowicka M, Buss T, Lichodziejewska-Niemierko M. The craniofacial necrotizing fasciitis after a minor trauma in an elderly white woman. *J Clin Exp Dent.* 2014;6:e307-9.
8. Wong J. Bevacizumab is linked to cases of necrotising fasciitis. *Lancet Oncol.* 2013;14:259.
9. Amer NM, Niaz R. Necrotizing fasciitis as a complication of taxanes: a case report. *Journal of Cancer Metastasis and Treatment.* 2018;4:34.