

Retropharyngeal Abscess

© Satvinder Singh Bakshi

All India Institute of Medical Sciences Mangalagiri, Andhra Pradesh, India

Keywords: Retropharyngeal abscess, incision and drainage, foreign body esophagus

Dear Editor,

A 73-year-old male presented with difficulty and pain in swallowing for 2 days associated with fever for one day. There was a history of fishbone ingestion before the onset of symptoms. On examination, he was febrile (103 °F) and partly edentulous. A laryngoscopic examination revealed a bulge in the posterior pharyngeal wall and pooling of secretions in the pyriform sinuses, no foreign body was seen. A lateral view X-ray of the neck revealed radiopaque widening in front of the cervical vertebrae (Figure 1, big arrow) with straightening of the cervical spine and mild narrowing of the tracheal airway (Figure 1, small arrow), no foreign body was seen. A contrast computed tomography (CT) scan revealed an abscess collection from the third to seventh cervical vertebrae and a small foreign body at the level of the fourth cervical vertebrae. The patient was started on intravenous ceftriaxone and metronidazole, fluids, and analgesics. The foreign body was removed and the abscess was drained transorally under general anesthesia. The patient was administered antibiotics for another 5 days and was asymptomatic at 6 months follow up.

Retropharyngeal abscess is a rare, but potentially life-threatening condition. Although it is more common in children below five years of age, the occurrence in adults is not rare (1). Children typically have an antecedent upper respiratory tract infection leading to suppurative cervical lymphadenitis and eventually retropharyngeal abscess. In adults, the etiology is linked to

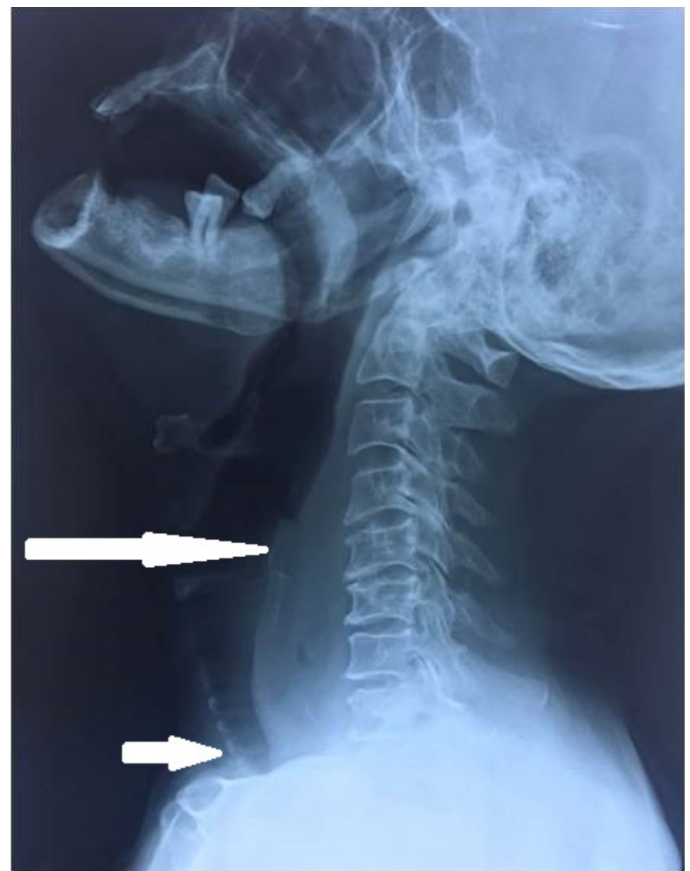


Figure 1. Lateral radiograph of the neck showing increased prevertebral space (big arrow), loss of cervical lordosis and mild tracheal compression (small arrow)



Corresponding Author: Satvinder Singh Bakshi, M.D., Assoc. Prof., All India Institute of Medical Sciences Mangalagiri, Andhra Pradesh, India
E-mail: saty.bakshi@gmail.com ORCID ID: orcid.org/0000-0003-4859-9588

Cite this article as: Bakshi SS. Retropharyngeal Abscess. Eurasian J Emerg Med. 2022;21(3):225-6.

Received: 28.04.2021
Accepted: 16.09.2021

trauma to the posterior pharynx either by a foreign body or an invasive procedure (2). The infection is polymicrobial; causative bacteria include group A *Streptococcus pyogenes*, *Staphylococcus aureus*, *Fusobacterium*, *Haemophilus* species. The initial evaluation is with lateral radiographs of the neck, the findings suspicious of an abscess include increased prevertebral space, loss of cervical lordosis due to spasm of prevertebral muscles, presence of gas or air-fluid level in the prevertebral space and presence of a foreign body (2). A CT scan with contrast gives a clear idea on the extent of abscess and can help locate radiolucent foreign bodies like fish bones (2). Complications include airway compromise, asphyxiation, mediastinitis, sepsis, esophageal perforation, etc (1). The patients should be hospitalized and started on antibiotics covering respiratory organisms and anaerobes. Surgical drainage is warranted in a large abscess, foreign body, and in patients with signs and symptoms of airway compromise (3). The approach can be intraoral or transcervical, depending on the degree of airway compromise, patient's general condition and availability of

resources (1). Early diagnosis and treatment ensure a favorable outcome, development of complications like mediastinitis, aspiration of pus point to a poor prognosis and high mortality rate (3).

Ethics

Informed Consent: Consent form was filled out by a participant.

Peer-review: Externally peer-reviewed.

Financial Disclosure: The author declared that this study received no financial support.

References

1. Reilly BK, Reilly JS. Retropharyngeal abscess: diagnosis and treatment update. *Infect Disord Drug Targets*. 2012;12:291-6.
2. Debnam JM, Guha-Thakurta N. Retropharyngeal and prevertebral spaces: anatomic imaging and diagnosis. *Otolaryngol Clin North Am*. 2012;45:1293-310.
3. Tanigawa T, Kano F, Inukai D, Kuruma T. Adult retropharyngeal abscess. *IDCases*. 2017;10:130-1.