

## Two and a Half Year Old Girl with Ischemic Stroke Due to Trauma (Lollipop Syndrome)

İki buçuk Yaşındaki Kız Çocuğunda Travmaya Bağlı İskemik İnme (Lolipop Sendromu)

Leila Rasi Marzabadi, Samad Shams Vahdati, Sara Alavi

Department of Emergency, Tabriz University of Medical Science, Imam Reza Hospital, Tabriz, Iran

### Abstract

Trauma to the soft palate and retropharyngeal tissue is an uncommon event during childhood. Neurological complications may occur following asymptomatic intra oral trauma. There is usually delay in diagnosis of non-penetrating traumas until neurological complications appear. In blunt carotid traumas, headache is the most common symptom. Other typical symptoms are unilateral neuralgic deficits such as hemiplegia, aphasia, or visual loss. Neurological complications are mostly caused by thrombus formation in the carotid artery. Early anticoagulation therapy and antiplatelet therapy are good non operative methods which can help cure trauma. A 2.5 year-old child is presented here, with hemiplegia and aphasia following by a blunt trauma of pharynx, caused by a fall whilst carrying a pencil in her mouth. The injury was without bleeding and the neurological symptoms appeared after 17 hours. Computed tomography of the brain revealed a large hypo dense area in the Middle Carotid Artery (MCA). Antiplatelet therapy was undertaken and good clinical results were obtained. (*JAEM 2012; 11: 238-40*)

**Key words:** Intra oral trauma, ischemic stroke, lollipop syndrome

### Özet

Çocukluk çağında yumuşak damak ve retrofaringeal dokulara travma ender bir olaydır. Semptomatik olmayan ağız içi travmalarını takiben nörolojik komplikasyonlar ortaya çıkabilir. Delici olmayan travmaların tanısında, genellikle nörolojik komplikasyonlar ortaya çıkana kadar gecikme olur. Künt karotis travmalarında, baş ağrısı en sık görülen semptomdur. Diğer tipik semptomlar afazi, görme kaybı veya hemipleji gibi tek taraflı nörolojik kayıplardır. Nörolojik komplikasyonların en sık nedeni karotis arterde trombus oluşumudur. Erken antikoagülasyon tedavisi ve antiplatelet tedavi, travmanın iyileşmesine yardımcı olabilecek cerrahi-dışı yararlı uygulamalardır. Burada, ağzında bir kalem varken düşme sonucu künt farinks travmasını takiben hemipleji ve afazisi olan 2.5 yaşındaki bir çocuk sunulmaktadır. Yaralanma kanamasızdı ve nörolojik semptomlar 17 saat sonra görüldü. Beynin bilgisayarlı tomografisi Orta Karotis Arterde (OKA) düşük dansiteli büyük bir alanı ortaya koydu. Antiplatelet tedavi başlandı ve iyi bir klinik sonuç elde edildi. (*JAEM 2012; 11: 238-40*)

**Anahtar kelimeler:** Ağız içi travma, iskemik inme, lolipop sendromu

### Introduction

Trauma to the soft palate and retropharyngeal tissue is an uncommon event during childhood. Neurological complications may occur following asymptomatic intra oral trauma. In blunt carotid traumas, neurological complications are mostly caused by thrombus formation in the carotid artery. this is a 2.5 year-old girl which is presented to emergency department because of right hemiplegia with history of pharyngeal trauma.

### Case Report

A 2.5-year-old girl was referred to Tabriz Pediatric Hospital because of her muscle hypotonicity on the right half of her body, and one week disability after she had fallen on a pencil, which had injected into her pharynx causing a blunt trauma with no bleeding.

Seventeen hours later her mother found her fallen with gazing eyes, and took her to a hospital in Ardebil. Then she was transferred to another hospital in Tabriz after she had vomited three times.

Her vital signs were as below:

Temperature: 36.5°C

Pulse rate: 93beats/min

Respiratory rate: 23times/min

Blood pressure: 80/60mmHg and her lab findings were PT: 12, PTT: 32, Plt: 287000, WBC: 8740, BS: 77.

On physical examinations, she had weakness of the right upper and lower limbs (right hemiplegia) and right hemifacial weakness and also significant uvula deviation to the left side. Her deep tendon reflexes (DTR) were decreased and right upper and lower DTR was 1+. Left plantar reflex was extensor but the right side was flexor. The girl was restless and also impatient and she had bruka aphasia.

Brain computed tomography (CT) was done (Figure 1).

**Correspondence to / Yazışma Adresi:** Samad Shams Vahdati, Department of Emergency, Tabriz University of Medical Science, Imam Reza Hospital, Tabriz, Iran  
Phone: 00984116581401 e.posta: sshamsv@yahoo.com

**Received / Geliş Tarihi:** 18.11.2010 **Accepted / Kabul Tarihi:** 27.01.2011

©Copyright 2012 by Emergency Physicians Association of Turkey - Available on-line at [www.akademikaciltip.com](http://www.akademikaciltip.com)  
©Telif Hakkı 2012 Acil Tıp Uzmanları Derneği - Makale metnine [www.akademikaciltip.com](http://www.akademikaciltip.com) web sayfasından ulaşılabilir.  
doi:10.5152/jaem.2011.068



Brain CT showed a large hypo dense area in the MCA distributive area, and on echocardiography there was no evidence of a clot in the left ventricle and no cardiac valve injury.

The color Doppler of carotid shows evidence of mild thrombosis in the upper portion of the carotid artery. Because of this, we started ASA (Acetylsalicylic Acid) 15 mg/day (dose which is used for prevention of transitional ischemic attack in adults).

## Discussion

Children often put sharp objects in their mouths which may cause injury to the internal carotid artery. The most common items responsible for injuries include toothbrushes, pens, sticks, toys and pencils and, in Asia, chopsticks. Injuries are most likely to be sustained by toddlers who are still unsteady on their feet and fall onto the object while it is in the mouth (1).

Age and sex distribution is a median age of 3 years, a mean age close to 4 years, and a male female ratio of approximately 2:1 (2).

The retro pharyngeal tissue is soft enough to allow injury to the carotid artery, and a foreign body could easily dislodge through this tissue (3). At first impression we may just see minor oral bleeding. Physicians treating patients with paratonsillar injuries should be aware that neurological complications may ensue (4), like hemiparesis due to traumatic thrombosis of the internal carotid artery. The cause of the traumatic occlusion may be direct damage to the artery (5). Carotid thrombosis is a rare complication occasionally seen in injuries of this kind (6), due to the close proximity of the internal carotid artery to the tonsillar bed, especially in the pediatric population, so such an injury is relatively more common in children (7).

The proposed mechanism of injury involves compression of the internal carotid artery between the object and the transverse process of an upper cervical vertebra. The resultant shearing effect causes an intimal tear in the vessel with subsequent thrombus formation and distal propagation of the thrombus into the cerebral

vasculature (8). The lucid interval (duration of normal neurologic status before the onset of symptoms) is believed to correlate with the time necessary for formation and propagation of thrombus, reportedly ranging from 3 to 60 hr after injury (8-10). If Carotid artery intimal injury could be detected before the onset of neurological signs and symptoms, anticoagulation therapy could be initiated to try to help prevent neurological sequel (11).

Classical symptoms of carotid artery injury are an initial lucid interval of consciousness before hemiplegia and aphasia. Neurological deterioration often occurs from 3 hr to 3 days after the initial injury (1). We were unable to identify any clinical factors that would help predict which children with oropharyngeal trauma are at high risk of developing neurological sequelae (11). Prior reports have linked seemingly innocuous oropharyngeal injuries to occult internal carotid artery damage with delayed onset of disastrous complications such as aphasia, hemiplegia and even death, in otherwise normal and healthy children (9). Because of the unknown incidence of the rare complication of neurological devastation following such injuries, it is unclear if patients with oropharyngeal trauma should be routinely screened for ICA injury (11). Internal carotid artery occlusion can be proved clinically only by angiography, which should be performed before therapy is undertaken. One third of children with internal carotid trauma after intraoral trauma died, the constant pathological finding was extension of the thrombus distally into the major intracranial arteries, with massive infarction of the hemisphere (4). Ordering computed tomographic angiography (CTA) should not be influenced by the severity of the injury because the most innocent appearing injuries may lead to devastating complications (9-11), so except for the rare case of an embedded foreign body the severity or appearance of wound should not necessarily influence the decision to image (11). Imaging obtained CTA seems to be a reasonable option as it provides a quick convenient and relatively inexpensive method (8). The sensitivity of CTA for detection of carotid artery injury when compared with contrast angiography has been shown as 68% for blunt cerebrovascular trauma (12, 13).

Management of intraoral trauma in children remains controversial treatment. Modalities used in the past included anticoagulation, surgical intervention and supportive care. Because of the rarity of traumatic internal carotid artery thrombosis, it is unclear which treatment is the most appropriate. Anticoagulation with heparin has yielded contradictory results, some investigators have recommended antiplatelet therapy with aspirin; surgical treatment includes thrombectomy, resection, and anastomosis and graft placement with varying success. Both surgical and medical treatments seem to benefit patients with minimal or evolving neurological deficits (14-16).

## Conclusion

In patients with neurological symptoms, especially after such accidents and injuries, blunt trauma to the carotid artery should be suspected. The mechanism or severity of the injury is not related with neurological involvement. Antiplatelet therapy could be a successful way of treatment of blunt carotid trauma.

## Conflict of Interest

No conflict of interest was declared by the authors.

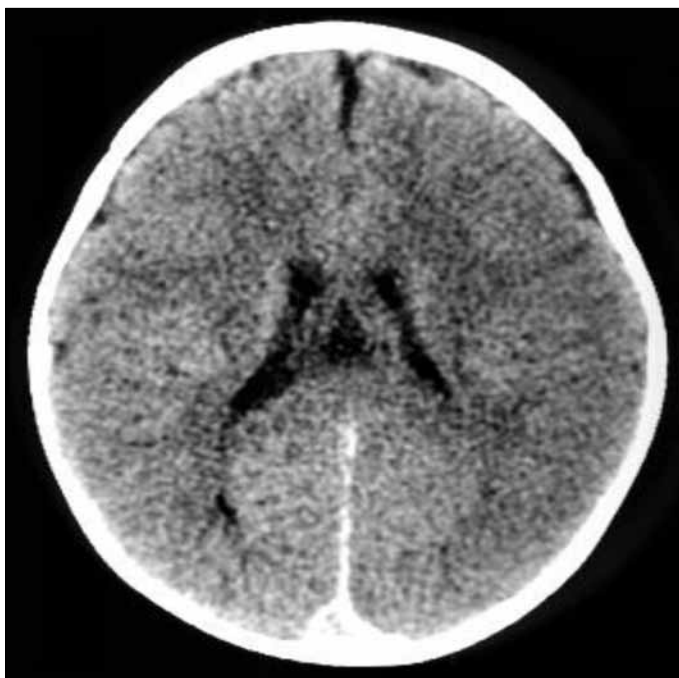


Figure 1. Brain CT

## References

1. Kosaki H, Nakamura N, Toriyama Y. Penetrating injuries to the oropharynx. *J Laryngol Otol* 1992; 106: 813-6. [\[CrossRef\]](#)
2. Radkowski D, McGill TJ, Healy GB, Jones DT. Penetrating trauma of the oropharynx in children. *Laryngoscope* 1993; 103: 991-4. [\[CrossRef\]](#)
3. Tsunoda K, Takanosawa M, Matsuda K. Aberrant internal carotid artery in the mouth. *Lancet* 1997; 350: 340. [\[CrossRef\]](#)
4. Carotid artery injuries caused by blunt trauma. *N Engl J Med* 1996; 274: 799.
5. Holyst J. Internal carotid artery occlusion due to intraoral trauma. *Acta Neurochir (Wien)* 1976; 33: 325-9. [\[CrossRef\]](#)
6. Bickeerstaff ER. Aetiology of acute hemiplegia in childhood. *Br Med J* 1964; 2: 82-7. [\[CrossRef\]](#)
7. Deutsch MD, Kriss VM, Willging JP. Distance between the tonsillar fossa and internal carotid artery in children. *Arch Otolaryngol Head Neck Surg* 1995; 121: 1410-2. [\[CrossRef\]](#)
8. Suskind DL, Tavill MA, Keller JL, Austin MB. Management of the carotid artery following penetrating injuries of the soft palate. *Int J Pediatr Otorhinolaryngol* 1997; 39: 41-9. [\[CrossRef\]](#)
9. Hengerer AS, DeGroot TR, Rivers RJ Jr, Pettee DS. Internal carotid artery thrombosis following soft palate injuries: a case report and review of 16 cases. *Laryngoscope* 1984; 94: 1571-5. [\[CrossRef\]](#)
10. Hellmann JR, Shott SR, Gootee MJ. Implant injuries of palate in children: review of 131 cases. *Int J Pediatr Otorhinolaryngol* 1993; 26: 157-63. [\[CrossRef\]](#)
11. Soose RJ, Simons JP, Mandell DL. Evaluation and management of pediatric oropharyngeal trauma. *Arch Otolaryngol Head Neck Surg* 2006; 132: 446-51. [\[CrossRef\]](#)
12. Biffil WL, Ray CE, Moore EE, Mestek M, Johnson JL, Burch JM. Noninvasive diagnosis of blunt cerebrovascular injuries: a preliminary report. *J Trauma* 2002; 53: 850-6.
13. Munera F, Soto JA, Palacio D, Velez SM, Medina E. Diagnosis of arterial injuries caused by penetrating trauma to the neck: comparison of helical CT angiography and conventional angiography. *Radiology* 2000; 216: 356-62.
14. Singhi P, Khandelwal NK, Mahajan V, Shahab S, Gupta V. Stroke following a bicycle injury. *Indian J Pediatr* 2007; 74: 856-8. [\[CrossRef\]](#)
15. Singer JI. Management strategy for penetrating oropharyngeal injury. *Pediatr Emerg Care* 1989; 5: 250-2. [\[CrossRef\]](#)
16. von Domarus H, Poeschel W. Impalement injuries of the palate. *Plast Reconstr Surg* 1983; 72: 656-8. [\[CrossRef\]](#)