

An Unexpected Appearance in Thoracic Computed Tomography

Toraks Bilgisayarlı Tomografide Beklenmeyen Bir Görüntü

Enver Özçete, Ferhat Çağırın, Hasan Mansur Durgun, Ayhan Özhasenekler
Department of Emergency Medicine, Faculty of Medicine, Dicle University, Diyarbakır, Turkey

A 77-year-old woman presented at our emergency department with a meat particle stuck in her throat. She was conscious, fully cooperative, and had normal vital signs and physical examination. As no foreign material was observed in the postero-anterior chest X-Ray, a thoracic computed tomography (CT) with intravenous (IV) contrast was obtained and given below. What is your diagnosis?

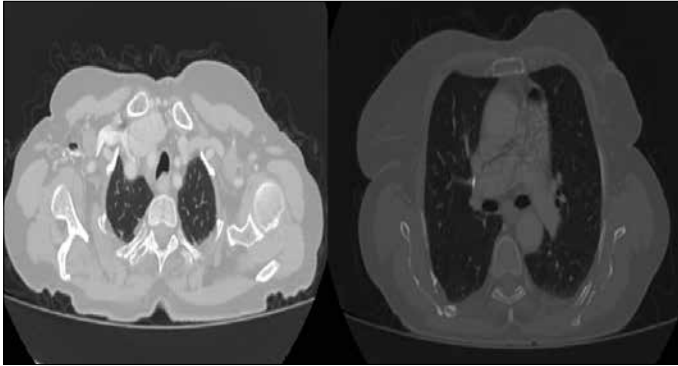


Figure 1. Axial thoracic CT cross sections

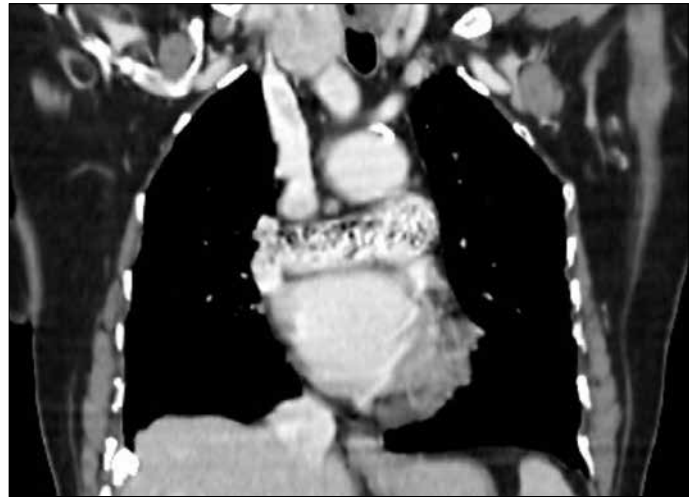


Figure 2. Coronal thoracic CT cross section



Correspondence to / Yazışma Adresi: Ayhan Özhasenekler, Department of Emergency Medicine, Faculty of Medicine, Dicle University, Diyarbakır, Turkey Phone: +90 412 248 80 01-4180 e.mail: drhasenek@mynet.com

Received / Geliş Tarihi: 15.07.2013 **Accepted / Kabul Tarihi:** 25.07.2013

©Copyright 2013 by Emergency Physicians Association of Turkey - Available online at www.akademikaciltip.com
©Telif Hakkı 2013 Acil Tıp Uzmanları Derneği - Makale metnine www.akademikaciltip.com web sayfasından ulaşılabilir.
doi:10.5152/jaem.2013.042